

Clinical Evaluation of Transcatheter Arterial Chemoembolization with 2-Day-soluble Gelatin Sponge Particles for Hepatocellular Carcinoma—Comparison with Insoluble Gelatin Sponge Particles

Nobuyuki Kawai, MD, Morio Sato, MD, Hiroki Minamiguchi, MD, Akira Ikoma, MD, Hiroki Sanda, MD, Kouhei Nakata, MD, Hirotatsu Sato, MD, Hinako Sakaguchi, MD, Motoki Nakai, MD, and Tetsuo Sonomura, MD

ABSTRACT

Purpose: To compare therapeutic effect, adverse events, and embolized hepatic artery impairment in transcatheter arterial chemoembolization between Lipiodol plus insoluble gelatin sponge particles (Gelpart) and Lipiodol plus 2-day-soluble gelatin sponge particles (2DS-GSPs).

Materials and Methods: In a single-center, prospective, randomized controlled trial, patients with hepatocellular carcinoma were assigned to the 2DS-GSP group or the Gelpart group. Radiographic response at 3 months per modified Response Evaluation Criteria In Solid Tumors was evaluated as the primary endpoint; secondary endpoints were safety (per Common Terminology Criteria for Adverse Events, version 4.0) within 3 months and hepatic branch artery impairment at the time of repeat chemoembolization (grade 0, no damage; grade I, mild vessel wall irregularity; grade II, overt stenosis; grade III, occlusion of more peripheral branch artery than subsegmental artery; grade IV, occlusion of subsegmental artery). Grade II, III, or IV indicated significant hepatic artery impairment.

Results: Thirty-seven patients with 143 nodules were randomized to the 2DS-GSP group and 36 patients with 137 nodules were randomized to the Gelpart group. No significant differences in patient background existed between groups. Target lesion response and overall tumor response in the 2DS-GSP and Gelpart groups were 77.7% versus 76.9% and 78.3% versus 77.8%, respectively, with no significant differences. No significant difference in adverse events existed between groups. Hepatic artery impairment was observed in 5% of patients in the 2DS-GSP group ($n = 32$) and in 16% in the Gelpart group ($n = 33$; $P < .001$).

Conclusions: Transcatheter arterial chemoembolization with 2DS-GSPs resulted in the same therapeutic and adverse effects as chemoembolization with Gelpart while causing significantly less hepatic artery impairment.

ABBREVIATIONS

CR = complete response, HCC = hepatocellular carcinoma, RECIST = Response Evaluation Criteria In Solid Tumors, PR = partial response, RF = radiofrequency, 2DS-GSP = 2-day-soluble gelatin sponge particle

From the Department of Radiology, Wakayama Medical University, 811-1 Kimiidera, Wakayamashi, Wakayama 641-8510, Japan. Received October 30, 2012; final revision received March 8, 2013; accepted March 11, 2013. Address correspondence to M.S.; E-mail: morisato@mail.wakayama-med.ac.jp

None of the authors have identified a conflict of interest.

© SIR, 2013

J Vasc Interv Radiol 2013; XX:■■■-■■■

<http://dx.doi.org/10.1016/j.jvir.2013.03.013>

Solid insoluble gelatin sponge particles are one type of embolic material used in transcatheter arterial chemoembolization for hepatocellular carcinoma (HCC) (1,2). A current problem in chemoembolization with gelatin sponge particles is that repeated chemoembolization commonly results in overt stenosis and/or occlusion of the hepatic artery, and induces the development of intra- and/or extrahepatic collateral arteries (3–7). Accordingly, catheterization to the HCC-feeding artery becomes difficult, thereby lessening the therapeutic effect and finally resulting in an inability to perform chemoembolization at

all. There is concern that this situation would affect the prognosis of patients with HCC (3–6).

We created solid soluble gelatin sponge particles by changing the temperature for heat cross-linkage to generate 2-day-soluble gelatin sponge, which has been assessed in vitro and in vivo (8). Clinically available gelatin sponge that is insoluble in saline solution for 2 weeks is created by heat cross-linkage at 150°C or greater; heat cross-linkage at less than 150°C results in soluble gelatin sponge. Gelatin sponges of various solubility times can be prepared by modulating the heating temperature (8). Two-day-soluble gelatin sponge was created by heat cross-linkage at 138°C.

The purpose of the present clinical study is to compare therapeutic effect, adverse events, and embolized hepatic artery impairment in transcatheter arterial chemoembolization between Lipiodol (Guerbet, Roissy, France) plus insoluble gelatin sponge particles and Lipiodol plus 2-day-soluble gelatin sponge particles (2DS-GSPs).

MATERIALS AND METHODS

Study Plan

The ethics committee of our institution granted approval for this prospective clinical study. We explained to patients that, regardless of the solubility of gelatin sponge, its use was primarily a clinical requirement and secondarily a part of a clinical investigation; all patients provided their written consent. This study was a single-center prospective, randomized, controlled trial. We targeted hypervascular HCC lesions as the objects of treatment. The primary endpoint was target lesion response and overall response by modified Response Evaluation Criteria In Solid Tumors (RECIST) at 3 months, and the secondary endpoints were safety and hepatic artery impairment based on repeat angiography.

We classified impairment of the embolized hepatic arteries as one of five grades: grade 0, no damage; grade I, mild vessel wall irregularity; grade II, overt stenosis;

grade III, occlusion of a peripheral branch artery more peripheral than a hepatic subsegmental artery; and grade IV, occlusion of subsegmental artery (Fig 1). Hepatic artery impairment was defined as grade II or greater, whereas a lack of hepatic artery impairment was defined as grade 0.

The following patients were eligible for inclusion in the study. (i) Patients with unresectable hypervascular HCC diagnosed within 2 months before chemoembolization by dynamic contrast-enhanced computed tomography (CT) or dynamic contrast-enhanced magnetic resonance (MR) imaging, which revealed early enhancement in the arterial phase and washout pattern in the portal or equilibrium phase; (ii) patients who were scheduled to undergo transcatheter arterial chemoembolization following assessment by surgeons, hepatologists, and interventional radiologists and who had four or more HCC nodules that were not suitable for radiofrequency (RF) ablation, hepatectomy, or radiation therapy; (iii) patients with no or medically controlled ascites; and (iv) patients with Child–Pugh class A/B disease and Child–Pugh scores of 5–10 and (v) Eastern Cooperative Oncology Group performance status of 0–2. Finally, (vi) previous treatments including transcatheter arterial chemoembolization were allowed in patients who had initially experienced complete response (CR) for 6 months and who had HCC recurrence after this time.

Exclusion criteria were as follows: (i) confirmed macroscopic vascular invasion or the presence of extrahepatic metastases; (ii) total bilirubin level greater than 3 mg/dL, creatinine level greater than 2 mg/dL, or platelet count lower than 50,000/mm³; (iii) presence of massive arterioportal shunt or complete hepatofugal blood flow; (iv) presence of stenosis and/or occlusion of celiac artery or hepatic branch artery; (v) presence of another malignancy; and (vi) allergy to gelatin.

At our outpatient clinic, patients underwent dynamic CT or MR imaging and plain chest radiography and were

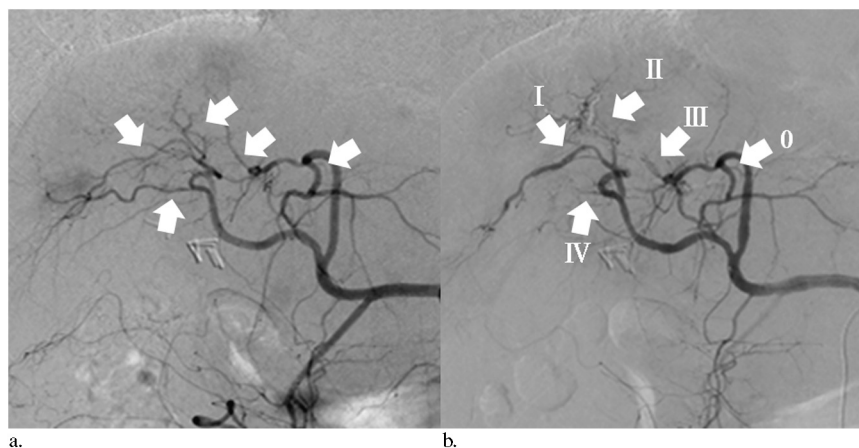


Figure 1. Degree of hepatic artery impairment. (a) Celiac arteriography followed by transcatheter arterial chemoembolization of hepatic branch arteries (arrows). (b) Celiac arteriography 3 months after chemoembolization depicts various degrees of hepatic artery impairment: no impairment (0); mild irregularity (I); overt stenosis (II); complete occlusion of subsegmental or more peripheral branch artery (III); and complete occlusion of segmental branch artery (IV).

scheduled for enrollment based on the findings of the imaging studies and the eligibility criteria. After admission to the hospital, the patients were immediately enrolled in the study. An independent doctor assigned patients to the 2DS-GSP group or the insoluble gelatin sponge particle (Gelpart; Nihonkayaku, Tokyo, Japan) group via random sampling by using an envelope registration system.

In evaluating the incidence of no hepatic arterial damage, sample size calculation was conducted such that a 30% difference between the 2DS-GSP and Gelpart groups would be expressed as a significant difference of $P < .05$. The estimated sample size was at least 175 embolized arteries, with a β -error of 0.20.

Chemoembolization was discontinued if the patients met any of the exclusion criteria. In addition, tumor vascular invasion or extrahepatic spread led to the discontinuation of chemoembolization.

Preparation of 2DS-GSPs

We used the least endotoxic gelatin (termed regenerative-medicine gelatin) that meets the standard for purified gelatin in the Japanese Pharmacopeia, according to the report of Takasaka et al (8). Regenerative-medicine gelatin fluid of molecular weight 50 kDa (Jellice, Sendai, Japan) was first freeze-dried for 48 hours to yield solid gelatin sponge and then heated at 138°C for 24 hours to cause heat-induced cross-linkage, leading to the production of 2-day-soluble gelatin sponge. The 2-day-soluble gelatin sponge was sliced into particles approximately 1 mm in size to create 2DS-GSPs. Insoluble gelatin sponge particles 1 mm in size (Gelpart), which are legally approved for clinical use in Japan, were used as a control. The 2DS-GSP and Gelpart were soaked in contrast medium (Iopamidol 370; Bracco, Milan, Italy) by pumping approximately 10 times with a three-way stopcock before embolization.

Transcatheter Arterial Chemoembolization Procedure

Transcatheter arterial chemoembolization was conducted by four interventional radiologists who had received training in transcatheter arterial chemoembolization at our institution and who had more than 3 years of experience in performing the procedure. Each patient underwent CT during angiography at a hybrid angiography/CT facility (INFX 8000-C Aquilion CX; Toshiba, Tokyo, Japan). The hybrid facility uses a common tabletop that enables angiography or CT to be performed without transferring the patient.

At all initial and follow-up treatments, the site of the HCC, the feeding artery, the presence or absence of portal tumor thrombus, hepatic artery impairment, and extrahepatic collateral vessels were identified in all patients by CT during aortography, angiography of the celiac artery and the superior mesenteric artery, and CT during arteriography, in which a 4-F catheter (pigtail or Rosch 2 type; Medikit, Tokyo, Japan) was inserted through a 4-F

sheath (Supersheath; Medikit). To obtain complete occlusion of the feeding arteries and to preserve liver function, highly selective catheterization was performed before chemoembolization with the use of a 2.2-F microcatheter (Tangent; Boston Scientific, Natick, Massachusetts) through a 4-F catheter. If multiple tumors were present in the right and left lobes, the catheter was advanced as close as possible to each tumor after chemoembolization, to at least the level of the segmental hepatic artery peripherally. If extrahepatic collateral arteries such as an inferior phrenic artery and an omental artery were identified as the feeding vessels, these were also catheterized as close as possible to the tumor with the use of a 4-F catheter (Mikaelsson; Medikit) and a 2.5-F microcatheter.

Four anticancer drugs—epirubicin (Kyowa Hakko, Tokyo, Japan), cisplatin (IA-Call; Nihonkayaku), mitomycin C (Kyowa Hakko), and 5-fluorouracil (Kyowa Hakko)—are covered by insurance in Japan, and the drug selection was determined by the doctor in charge of the patient. When only epirubicin was selected, epirubicin plus Lipiodol emulsion was prepared by mixing 5 mL of Lipiodol with 50 mg of epirubicin in 5 mL of contrast medium. When only cisplatin was selected, cisplatin plus Lipiodol emulsion was prepared by mixing 5 mL of Lipiodol with 50 mg of cisplatin in 5 mL contrast medium. When all four anticancer drugs were selected, epirubicin, cisplatin, and mitomycin C plus Lipiodol emulsion was prepared by mixing 5 mL of Lipiodol with 20 mg of epirubicin, 10 mg of mitomycin C, and 50 mg of cisplatin dissolved in 5 mL of contrast medium before adding 250 mg of 5-fluorouracil in 5 mL of saline solution. Each emulsion was created by pumping with a three-way stopcock. Lipiodol was further mixed with the anticancer drugs when a volume of Lipiodol greater than 5 mL was required.

Chemoembolization with Lipiodol followed by 2DS-GSPs or Gelpart to an endpoint of blood flow stasis was scheduled for each patient. Total Lipiodol volume was calculated according to total HCC volume: for an HCC nodule 1 cm in diameter, we used approximately 1 mL of Lipiodol. To avoid liver damage, we limited the maximum Lipiodol dose to 10 mL and performed chemoembolization as selectively as possible, with gelatin sponge particles 1 or 2 mm in size. When the 10-mL Lipiodol dose limit was reached in the initial procedure before all tumors were treated, a second procedure was performed 7–10 days later to cover all the tumors. In this case, the total volume of Lipiodol in two procedures was limited to 20 mL.

Before chemoembolization, 5-HT₃ (ie, serotonin) antagonists were given as antiemetic treatment. Each patient received 1,000 mL of intravenous fluid over a period of at least 4 hours on the day before chemoembolization; between the completion of chemoembolization and the next morning, patients received 1,500 mL of intravenous fluid. Prophylactic antibiotics (cefazolin; CEZ, Nipro-pharma, Tokyo, Japan) were administered in all patients for 3 days after the procedure.

Evaluation of Adverse Events, Therapeutic Effect, and Hepatic Artery Impairment

Physical examination, blood tests, and liver function tests were conducted routinely during the hospital stay before and at least 2, 5, and 10 days after chemoembolization, and every 3 months after discharge. Adverse events related to chemoembolization were graded according to the National Cancer Institute Common Terminology Criteria for Adverse Events, version 4.0. Tumor response was evaluated by comparing follow-up dynamic CT imaging with the CT scans obtained immediately after and during chemoembolization. In CT imaging assessment of treatment efficacy, multiphase CT imaging was obtained every 3 months, and the images were reviewed by two radiologists, each with more than 10 years of experience in abdominal image diagnosis. Multiphase CT was conducted by using a multidetector CT scanner (LightSpeed VCT 64; GE Healthcare, Milwaukee, Wisconsin) with a 64×0.625 -mm detector configuration. The four-phase acquisition included unenhanced CT and three phases (arterial, portal, and equilibrium) of contrast-enhanced CT. Axial images (thickness, 5 mm; reconstruction interval, 5 mm) were sent to the picture archiving and communication system and to workstations.

Tumor enhancement on the arterial phase, the extent of Lipiodol accumulation in the HCC nodules, and three-dimensional reduction in tumor size were determined. Target lesion response and overall response were evaluated at 3 months after chemoembolization according to modified RECIST (9).

Patients without CR required repeat chemoembolization. The frequency of hepatic artery occlusion was determined

in both groups at the time of repeat angiography. Hepatic branch artery abnormality was evaluated at each chemoembolization session by comparing angiographic findings before the current chemoembolization with those before the previous chemoembolization. The presence of hepatic artery impairment was assessed on digital subtraction angiographic images by consensus of two radiologists, each with more than 10 years of experience with the chemoembolization procedure and neither of whom performed chemoembolization in the present study. The radiologists were not blinded to evaluate hepatic artery impairment. We did not intend to evaluate differences in survival between the 2DS-GSP and Gelpart groups.

Statistical Analyses

A Student *t* test was used to compare the continuous variables of age, body weight, HCC size, Lipiodol volume, and number of collateral vessels between patients in the 2DS-GSP and Gelpart groups. The Mann–Whitney *U* test was used to compare the number of chemoembolization procedures for the ordinal scale of discrete variables between patients in the 2DS-GSP and Gelpart groups. A Fisher exact test or Pearson χ^2 test was used to compare categorical variables of sex, Child–Pugh classification, hepatitis, α -fetoprotein value, protein induced by vitamin K absence or antagonist II value, number of previous treatments, clinical stage, number of HCC nodules, segment distribution of HCC nodules, overall tumor response, and adverse events, including hepatic artery abnormality, between patients in the two groups. For each analysis, *P* values lower than .05 were considered statistically significant.

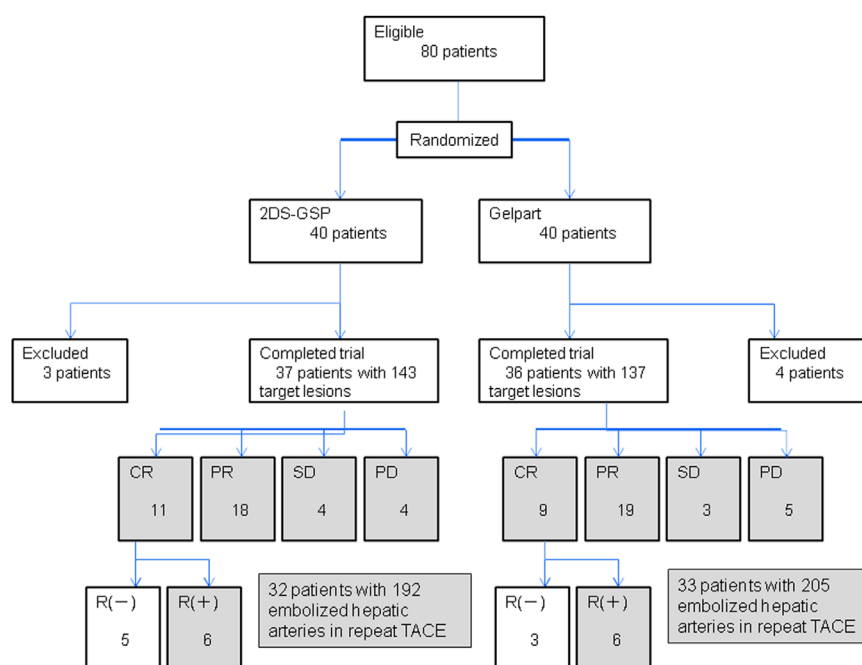


Figure 2. Patient flowchart (CR = complete response, PD = progressive disease, PR = partial response, R = recurrence, SD = stable disease).

RESULTS

Randomized Patients

Eighty patients with HCC were enrolled in the study during September 2009 and February 2011. The data were analyzed in April 2012. The trial ended because the sample size of hepatic artery impairment was fulfilled. Forty patients with HCC were assigned to the 2DS-GSP group and 40 were assigned to the Gelpart group (Fig 2). Three patients in the 2DS-GSP group and four patients in the Gelpart group were excluded based on differences in dynamic CT or MR findings at the outpatient clinic and those of CT during aortography and CT during arteriography before chemoembolization and when RF ablation was performed following chemoembolization, despite the requirement that nodules were not suitable for RF ablation. Causes for exclusion in the 2DS-GSP group were portal tumor thrombi observed on CT during arteriography before chemoembolization ($n = 2$) and RF ablation after chemoembolization ($n = 1$). Causes for exclusion in the Gelpart group were portal tumor thrombi observed on CT during arteriography ($n = 2$), marked arteriportal shunt observed on CT during aortography ($n = 1$), and RF ablation performed after chemoembolization ($n = 1$). Following exclusions, 37 patients with 143 nodules were randomized to undergo chemoembolization with 2DS-GSP and 36 patients with 137 nodules were randomized to undergo chemoembolization with Gelpart.

Patient Backgrounds and Tumor Characteristics

Table 1 compares patient backgrounds between the 2DS-GSP and Gelpart groups in terms of age, viral hepatitis, Child–Pugh classification, United Network for Organ Sharing clinical stage, and previous curative treatment. No statistically significant differences were found between the two groups with respect to patient background ($P = .252$ –.816).

Table 2 compares HCC nodule characteristics between the 2DS-GSP and Gelpart groups in terms of nodule number, size, and the anticancer drugs used. We found no statistical difference between the two groups ($P = .545$ –.964).

Target Lesion Response

Table 3 shows radiographic response in the five largest target lesions at 3 months according to modified RECIST. CR or partial response (PR) was achieved in 111 nodules (77.7%) in the 2DS-GSP group: CR in 66 nodules (46.2%) and PR in 45 nodules (31.5%). CR or PR was achieved in 104 nodules (75.9%) in the Gelpart group: CR in 61 nodules (44.5%) and PR in 43 nodules (31.4%). There was no significant difference between groups in terms of target lesion response ($P = .914$).

Overall Tumor Response

Table 4 shows overall response (target lesions, nontarget lesions, and new lesions) at 3 months per modified

Table 1. Demographic and Clinical Details of Study Patients

Characteristic	2DS-GSP (n = 37)	Gelpart (n = 36)	P Value
Sex			.433*
Male	25	28	
Female	12	8	
Age			.323 [†]
Mean ± SD	72 ± 7	70 ± 8	
Range	60–84	54–87	
Hepatitis			.588 [‡]
C	28	28	
B	3	1	
Non-B/non-C	6	7	
Child–Pugh class			.476 [‡]
A	26	22	
B	11	13	
C	0	1	
UNOS clinical stage			.493 [‡]
I	0	0	
II	35	36	
III	2	0	
A/III	0	0	
B/III	0	0	
C/IV	0	0	
AFP (ng/mL)			
< 20	9	13	–
≥ 20	16	14	.528 [‡]
> 200	12	9	–
PIVKA II (mAU/mL)			
< 40	7	12	–
≥ 40	21	14	.252 [‡]
> 400	9	10	–
Previous treatment			
Surgical hepatectomy	4	5	.736 [‡]
Chemoembolization	33	31	.736 [‡]
PEI	6	8	.564 [‡]
RF ablation	21	19	.816 [‡]

AFP = α -fetoprotein, PEI = percutaneous ethanol injection, PIVKA = protein induced by vitamin K absence, RF = radiofrequency; 2DS-GSP = 2-day-soluble gelatin sponge particle; UNOS = United Network for Organ Sharing.

*Fisher exact test.

[†]Student *t* test.

[‡] χ^2 test.

RECIST. CR or PR was achieved in 29 patients (78.3%) in the 2DS-GSP group: CR in 11 (29.7%) and PR in 18 (48.6%). CR or PR was achieved in 28 patients (77.8%) in the Gelpart group: CR in nine (25.0%) and PR in 19 (52.8%). There was no significant difference between groups in terms of overall response ($P = .926$).

Adverse Events

Table 5 compares adverse events between the 2DS-GSP and Gelpart groups. No significant difference was found between the two groups ($P = .543$ –.723), and a grade IV or greater adverse event was not observed in either group.

Table 2. Characteristics of Tumor Nodules and Anticancer Drugs Administered

Characteristic	2DS-GSP (n = 37)	Gelpart (n = 36)	P Value
No. of nodules			.964*
1	0	0	
2	5	6	
3	9	8	
4	9	9	
5–10	8	9	
≥ 10	6	4	
Nodule size (mm)	22.3 ± 12.9	21.5 ± 11.9	.545 [†]
Anticancer drugs			
Epirubicin	14	13	–
Cisplatin	10	12	.833*
Epirubicin/cisplatin/ mitomycin-C/5-FU	13	11	–

5-FU = 5-fluorouracil, 2DS-GSP = 2-day-soluble gelatin sponge particle.

* χ^2 test.

[†] Student *t* test.

Grade III aspartate aminotransferase and alanine aminotransferase level elevations were found in both groups, and grade III fever occurred in the Gelpart group.

Hepatic Artery Impairment

During the follow-up study, 32 patients with 192 embolized hepatic arteries in the 2DS-GSP group and 33 patients with 205 embolized arteries in the Gelpart group underwent follow-up angiography for suspected recurrence (Fig 2). Table 6 compares hepatic artery impairment between the 2DS-GSP and Gelpart groups; we found a significant difference between groups ($P < .001$). No hepatic artery damage occurred in 79% of the 2DS-GSP group ($n = 192$) and 45% of the Gelpart group ($n = 205$; Table 6). The incidences of hepatic artery impairment of grade II or greater were 5% in the 2DS-GSP group and 16% in the Gelpart group (Figs 3, 4).

Table 3. Target Lesion Response per Modified RECIST

Response	2DS-GSP (n = 143)	Gelpart (n = 137)	P Value
CR	66 (46.2)	61 (44.5)	–
PR	45 (31.5)	43 (31.4)	–
SD	14 (9.8)	17 (12.4)	.914*
PD	18 (12.6)	16 (11.7)	–

Values in parentheses are percentages.

CR = complete response, PD = progressive disease, PR = partial response, RECIST = Response Evaluation Criteria In Solid Tumors, SD = stable disease, 2DS-GSP = 2-day-soluble gelatin sponge particle.

* χ^2 test.

Table 4. Overall Response per Modified RECIST

Response	2DS-GSP (n = 37)	Gelpart (n = 36)	P Value
CR	11 (29.7)	9 (25.0)	–
PR	18 (48.6)	19 (52.8)	–
SD	4 (10.8)	3 (8.3)	.926*
PD	4 (10.8)	5 (13.9)	–

Values in parentheses are percentages.

CR = complete response, PD = progressive disease, PR = partial response, RECIST = Response Evaluation Criteria In Solid Tumors, SD = stable disease, 2DS-GSP = 2-day-soluble gelatin sponge particle.

* χ^2 test.

DISCUSSION

Factors previously reported as causing hepatic artery impairment after transcatheter arterial chemoembolization are accumulated dose of anticancer drug per hepatic artery, the number of anticancer drugs, and Child–Pugh score (10,11). These previous studies were conducted with the use of insoluble gelatin sponge particles (eg, Gelpart, Spongel [Astellas Pharma, Tokyo, Japan], Gelfoam [Pfizer, New York, New York]). Insoluble gelatin sponge particles have multiple pores and cause embolism by secondary thrombosis of pores in the hepatic artery, after which the gelatin sponge particles are recognized as a foreign body and absorbed in the vascular wall in approximately 1 month (8). That is, the absorption process of the gelatin sponge particle itself results in intimal thickening and consequent narrowing of the arterial lumen. In a clinical study (10,11) that used insoluble gelatin sponge, the embolized hepatic arteries were recanalized 3 weeks after chemoembolization in 70%–80% of cases. Maeda et al (10) reported that chemoembolization with epirubicin 50 mg plus insoluble gelatin sponge particles caused hepatic artery impairment with overt stenosis and/or occlusion in 48% of cases, and Sahara et al (11) reported that chemoembolization with insoluble gelatin sponge particles plus 41.7 mg epirubicin and chemoembolization with insoluble gelatin sponge particles plus multiple anticancer drugs (epirubicin 26.7 mg, mitomycin C 6.0 mg, cisplatin 31.1 mg, 5-fluorouracil

Table 5. Adverse Events per CTCAE Version 4.0

Event	2DS-GSP (n = 37)					Gelpart (n = 36)					P Value*
	Grade					Grade					
	1	2	3	4	5	1	2	3	4	5	
Fever	15	9	0	0	0	13	8	2	0	0	.543
AST	13	6	3	0	–	14	9	2	0	–	.696
ALT	15	7	4	0	–	13	10	2	0	–	.723
Total bilirubin	12	9	0	0	–	13	11	0	0	–	.671
Creatinine	3	0	0	0	–	3	1	0	0	–	.592

ALT = alanine aminotransferase, AST = aspartate aminotransferase, CTCAE = Common Terminology Criteria for Adverse Events, 2DS-GSP = 2-day-soluble gelatin sponge particle.

* χ^2 test.

Table 6. Hepatic Artery Impairment

Group	Grade				
	0	I	II	III	IV
2DS-GSP (n = 192)	152 (79)	30 (16)	8 (4)	2 (1)	0
Gelpart (n = 205)	92 (45)	80 (39)	24 (12)	7 (3)	2 (1)

Values in parentheses are percentages. $P < .001$ by χ^2 test is the difference between both groups on hepatic artery impairment overall.

2DS-GSP = 2-day-soluble gelatin sponge particle.

199.2 mg) caused hepatic artery impairment in 17% and 34% of cases, respectively. In the present study, chemoembolization with insoluble gelatin sponge particles plus anticancer drugs caused hepatic artery stenosis and/or occlusion in 16% of cases. Differences in the incidence of hepatic artery impairment are considered to depend on the different types of anticancer drugs and their volumes (10,11).

Gelatin with the least possible endotoxicity and antigenicity (ie, regenerative-medicine gelatin) was generated in 2007 (12), enabling the creation of soluble gelatin sponge with the use of this regenerative-medicine gelatin (8). The solubility time was controlled by heating at temperatures of 110°C–155°C to develop heat cross-linkage, and the safety of soluble gelatin sponge particles was assured in vitro and in vivo (8). Takasaka et al (8) reported the prominence of intra- and extrahepatic collateral arteries on angiography performed 3 days after embolization with insoluble gelatin sponge, whereas no collateral arteries were found with 2DS-GSPs made by heating at 138°C for 24 hours for heat-induced cross-linkage. Therefore, we used 2DS-GSPs in the present clinical study, with the result of a significantly lower incidence of overt stenosis and/or occlusion in the 2DS-GSP group (5%) compared with the Gelpart group (16%). We consider that, although the hepatic artery impairment observed in the 2DS-GSP group can be attributed to the

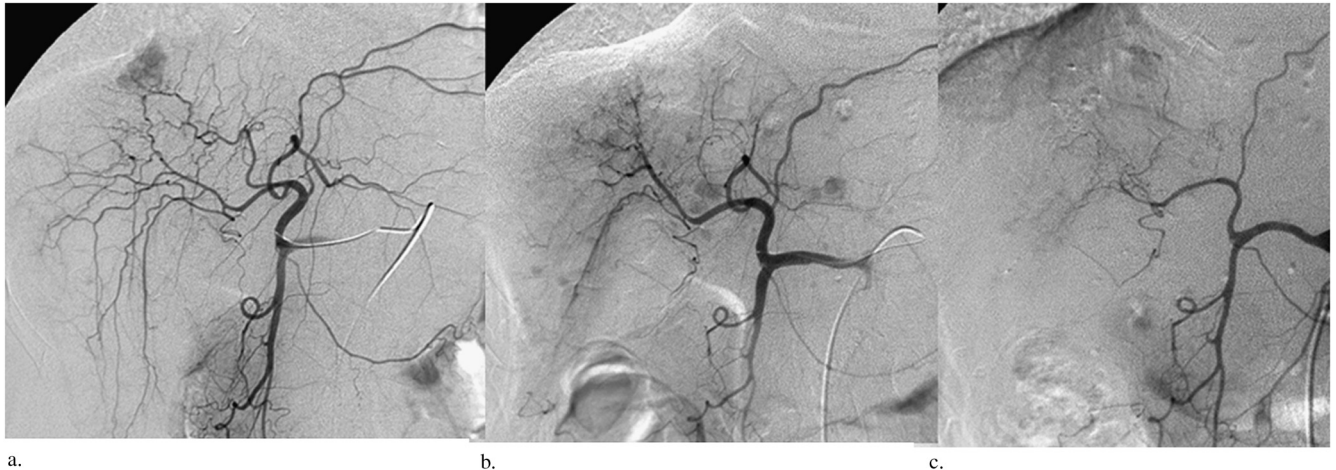


Figure 3. Hepatic arteriography images before transcatheter arterial chemoembolization (a), 6 months after the first chemoembolization (b), and 9 months after the second chemoembolization (c) in a 68-year-old man in the Gelpart group depict the gradual advancement of hepatic artery impairment, leading to complete occlusion (grade IV) of segmental branch arteries.

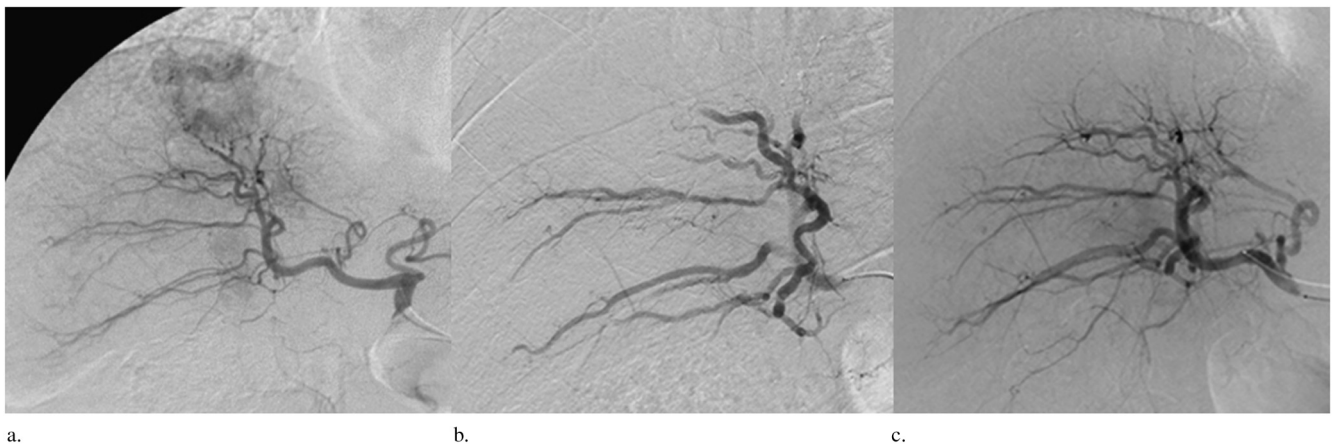

Figure 4. Hepatic arteriography in a 68-year-old man in the 2DS-GSP group. (a) Proper hepatic arteriography depicts tumor staining. (b) Right hepatic arteriography immediately after transcatheter arterial embolization with soluble gelatin sponge particles depicts occlusion of the hepatic artery and disappearance of the tumor. (c) Right hepatic arteriography obtained 3 years later depicts no hepatic artery impairment.

anticancer drugs, Lipiodol, secondary thrombosis, and microcatheter injury, chemoembolization with 2DS-GSPs is preferable because it has a lower incidence of hepatic artery impairment, resulting in repressed development of intra- and/or extrahepatic blood supply.

To our knowledge, no previous studies have documented the time required to cause ischemic necrosis in viable HCC. In the comparison of therapeutic effect and adverse events in the present study, no significant differences were found between the Gelpart and 2DS-GSP groups. Our results suggest that viable HCCs suffer ischemic damage within 48 hours of interruption of arterial blood flow, and also that chemoembolization with 2DS-GSPs may enable avoidance of the potential difficulty of the procedure that results from occlusion of the whole hepatic arteries after chemoembolization with insoluble gelatin sponge particles. In short, chemoembolization with 2DS-GSPs has potential to increase the opportunities to perform chemoembolization.

There are limitations to the present study. We merely clarified the HCC nodule response and overall tumor response at 3 months after chemoembolization. A longer follow-up period is needed to clarify whether extending the opportunity to perform chemoembolization with 2DS-GSPs results in longer survival. Another limitation is that the various operators selected different anticancer drugs, which is a weakness of this prospective study. In addition, even though no significant difference was found between the two groups in terms of the incidence of previous chemoembolization and the type of anticancer drug used in the study, the results in terms of therapeutic effect and hepatic artery impairment may include bias because of previous chemoembolization, operator choice of anticancer drugs, different assessment periods, and nonblinded consensus assessment of hepatic artery impairment. However, the fact that there was no significant difference in tumor response between the two groups is crucial when deciding whether to conduct further studies to explore survival rates. Another limitation is that our investigation was a prospective study

conducted at a single institution, rather than a randomized study at multiple institutions.

In conclusion, no significant difference regarding adverse events, HCC nodule response, or overall tumor response at 3 months was found between the 2DS-GSP and Gelpart chemoembolization groups. However, significantly less damage to the hepatic branch artery was found on follow-up angiography in the 2DS-GSP group compared with the Gelpart group.

REFERENCES

1. Yamada R, Sato M, Kawabata M, Nakatsuka H, Nakamura K, Takashima S. Hepatic artery embolization in 120 patients with unresectable hepatoma. *Radiology* 1983; 148:397–401.
2. Takayasu K. Superselective transarterial chemoembolization for hepatocellular carcinoma: recent progression and perspective. *Oncology* 2011; 81:105–110.
3. Nakai M, Sato M, Kawai N, et al. Hepatocellular carcinoma: involvement of the internal mammary artery. *Radiology* 2001; 219:147–152.
4. Kim HC, Chung JW, Lee W, Jae HJ, Park JH. Recognizing extrahepatic collateral vessels that supply hepatocellular carcinoma to avoid complications of transcatheter arterial chemoembolization. *Radiographics* 2005; 25(suppl):S25–S39.
5. Park SI, Lee DY, Won JY, Lee JT. Extrahepatic collateral supply of hepatocellular carcinoma by the intercostal arteries. *J Vasc Interv Radiol* 2003; 14:461–468.
6. Miyayama S, Matsui O, Taki K, et al. Extrahepatic blood supply to hepatocellular carcinoma: angiographic demonstration and transcatheter arterial chemoembolization. *Cardiovasc Intervent Radiol* 2006; 29:39–48.
7. Kim HC, Chung JW, An S, et al. Left inferior phrenic artery feeding hepatocellular carcinoma: angiographic anatomy using C-arm CT. *AJR Am J Roentgenol* 2009; 193:W288–W294.
8. Takasaka I, Kawai N, Sato M, et al. A new soluble gelatin sponge for transcatheter hepatic arterial embolization. *Cardiovasc Intervent Radiol* 2010; 33:1198–1204.
9. Lencioni R, Llovet JM. Modified RECIST (mRECIST) assessment for hepatocellular carcinoma. *Semin Liver Dis* 2010; 30:52–60.
10. Maeda N, Osuga K, Mikami K, et al. Angiographic evaluation of hepatic arterial damage after transarterial chemoembolization for hepatocellular carcinoma. *Radiat Med* 2008; 26:206–212.
11. Sahara S, Kawai N, Sato M, et al. Prospective evaluation of transcatheter arterial chemoembolization (TACE) with multiple anti-cancer drugs (epirubicin, cisplatin, mitomycin c, 5-fluorouracil) compared with TACE with epirubicin for treatment of hepatocellular carcinoma. *Cardiovasc Intervent Radiol* 2012; 35:1363–1371.
12. Kanayama Y, Aoki C, Sakai Y. Development of low endotoxin gelatin for regenerative medicine. *Biol Pharm Bull* 2007; 30:237–241.